

Endoscopic-Powered Technique for Closed Reduction Rhinoplasty

ASHRAF MABROUK, M.D.* and SALAH NASSER, M.D.**

The Departments of Otorhinolaryngology and Plastic Surgery**, Faculty of Medicine, Ain Shams University, Cairo.*

ABSTRACT

The aim of this paper is to demonstrate and evaluate an endoscopic-powered technique for lowering the nasal hump during closed cosmetic rhinoplasty surgery. Twenty patients (12 males and 8 females) ranging in age between 19 to 38 years (with a mean age of 23 years) and having high nasal humps were subjected to endoscopic exposure of their nasal dorsa through limited (partial) transfixion and intercartilagenous incisions. Then, a standard microdebrider was used for reducing the nasal humps. The technique is described in details and the patients were followed up clinically for an average 18 months postoperatively for assessment of results. The nasal endoscopes allowed direct visualization of the nasal dorsum without the need for external incisions. Also, this facilitated fine remodeling of the nasal hump using the standard microdebriders. The intraoperative bleeding and postoperative edema and ecchymosis were reduced in all patients. All the patients in this study had good acceptable aesthetic postoperative results with no complications encountered in any of them. In this respect, the endoscopic technique for nasal dorsum reduction is an easy, safe and efficient approach. It allows direct vision, permitting precise contouring of the nasal dorsum using the standard microdebriders and easy visualization by associates.

INTRODUCTION

In the field of facial surgery, operations that require guesswork can result in unexpected complications. One example of such "blind" facial surgery is the reduction of the nasal dorsum using rasps or chisels during standard closed rhinoplasty. The postoperative results of such conventional closed rhinoplasty techniques are controlled by the surgeon's visual perception or manual dexterity; therefore, an experienced surgeon is indispensable in this elaborate operations [1].

On the other hand, although open structure rhinoplasty techniques allow direct visualization [2], they require external skin incision and more extensive dissection. This is associated with more intraoperative bleeding and more marked postoperative facial ecchymosis and swelling following

such extensive exposure. However, the major disadvantage of the open rhinoplasty is the difficulty to define the correct dorsal line (i.e. the nasofrontal angle) and dorsum-tip relationship once the skin is elevated. Also, the external skin incision in such technique has the drawbacks of any skin incision elsewhere [3]. In an Arabian population study [4], the percentage of unsatisfactory collumellar scar of open rhinoplasty was 22%, which is high enough to advocate its avoidance.

With the great advances in technology of the fibro-optic endoscopes, previously inaccessible structures can be nowadays brought into direct vision through minimally invasive approaches. Also, the new trend in rhinology is the use of powered instruments (i.e. microdebriders) for surgical treatment of the nose and paranasal sinuses [5]. The application of such high technology instruments in rhinoplasty surgery is not obviously discussed and assessed in the available literature. So, the aim of this study is to use an endoscopic method for contouring the nasal dorsum using the standard microdebriders during cosmetic closed technique rhinoplasty and to assess its benefits and its results.

PATIENTS AND METHODS

Twenty patients were included in this study. They were 12 males and 8 females. Their ages ranged between 19 and 38 years (with a mean age of 23 years). All the patients had a large nasal hump of variable degrees.

Surgical instrumentation:

This involves the use of 4 mm 30° rigid nasal endoscope for visualization of the nasal dorsum, which is connected with a digital camera and video-monitor. The procedure is performed with a powered microdebrider to remove both soft tissue and

bone of the nasal dorsum. A standard serrated sinus blade and a shielded cutting bur are used in performing the technique (Fig. 1). Traditional nasal surgical instruments are also needed for various portions of the procedure. The powered equipment used in this study is manufactured by Stryker while nasal endoscopes; digital camera and videomonitor are manufactured by Wolf.

Surgical technique:

About half-an-hour preoperatively, oxymetazoline spray 0.05% is applied in the nose of the patients in the holding area. After general anesthesia is induced, the nose is packed bilaterally with cotton pledgets lightly soaked with epinephrine 1:10000 the pledgets are left in place for 10 minutes and then removal. Next, the nasal septum, pyriform apertures, nasal vestibule and nasal dorsum are infiltrated with 1% xylocaine and 1:100000 epinephrine. Then 10 minutes are allowed to pass for the local vasoconstrictor to take place, during which trimming of the nasal vibrissae with a fine scissor is done. Also, hypotensive anesthesia techniques are very helpful to control the intraoperative bleeding.

A limited (partial) transfixion incision (Fig. 2-A) is performed from the caudal end of the anterior septal angle to a point just short of the medial crural attachment to the caudal septum. However, a complete transfixion incision (Fig. 2-B), with its extension to the nasal spine, is rarely needed when more exposure is required as in correction of marked caudal septal dislocation of the nasal spine and in repair of overprojected tip. Then, the septal incision is extended into bilateral standard intercartilagenous incisions in the nasal vestibule (Fig. 2-C). Through this incision a pocket is created just superficial to the nasal dorsum using a fine curved scissor.

Next, an Aufricht's retractor is inserted into this pocket and held by an assistant. Then, the endoscope is positioned through the incision to visualize the nasal dorsum. With a sharp scissor the soft tissues are gently separated and freed from the underlying cartilage and bone up to the fronto-nasal junction, identifying the angular vessels (Fig. 3). These arteries can easily be protected and preserved, or if needed they can be cauterized and divided under direct vision.

The anatomy and contour of the nasal dorsum are then examined both by endoscopic inspection (Fig. 4) and by palpation and resection and shaping are planned. The microdebrider (Fig. 5) is then inserted into the incision using the 4.0 mm serrated

sinus blade to remove the cartilaginous hump and any soft tissues adherent to the bony dorsum. The microdebrider is used in the oscillating mode.

After cleaning the soft tissues well, the standard sinus blade is removed and a shielded cutting bur is attached to the microdebrider hand-piece. This is reinserted through the incision and used to shave down the bone that requires thinning and contouring using the bur in the forward mode. With endoscopic visualization, the dorsal bone can be reshaped precisely, allowing enhancement of the aesthetic appearance of the nose. Periodic irrigation of the bur with normal saline solution is needed as bone dust accumulates in the flutes of the bur, decreasing its efficiency in shaving the bone.

Once the nasal dorsum work is finished, any needed tip work can be conducted at this time. Also, the medial and lateral osteotomies are performed with the conventional hand-held osteotomes. When irregularities occur in dorsal contour following the standard osteotomies (i.e. medial and lateral) the microdebrider with the cutting bur can be easily used to refine the bony dorsum.

At the end of the procedure, the incisions are closed with 2 or 3 stitches of 5/0 vicryl sutures on a cutting needle. External nasal splinting is used for one week postoperatively and if septoplasty is performed internal silastic splints for the septum are also used. Light nasal packing is done and the patient is sent home on antibiotic, analgesic and uses ice compresses on the face for the first 24 hours.

RESULTS

All the patients involved in this study had successful precise reduction of their nasal humps using the endoscopic technique with an excellent aesthetic results (Fig. 6). The postoperative ecchymosis and edema of the face were obviously reduced in all patients in this study. No complications related to the endoscopic technique of reduction rhinoplasty were detected in this series of patients.

DISCUSSION

The use of endoscopes in the practice of rhinology became popular in Europe since the early 1970s [6,7], while in America in mid 1980s [8,9]. At the present time, functional endoscopic sinus surgery has become the most common surgical technique for the sinuses due to its safety and efficacy [10]. This has been associated with increased understanding and appreciation of nasal

Fig. (1): The powered instrumentation showing the ends of shielded serrated blade (A) and cutting bur (B).

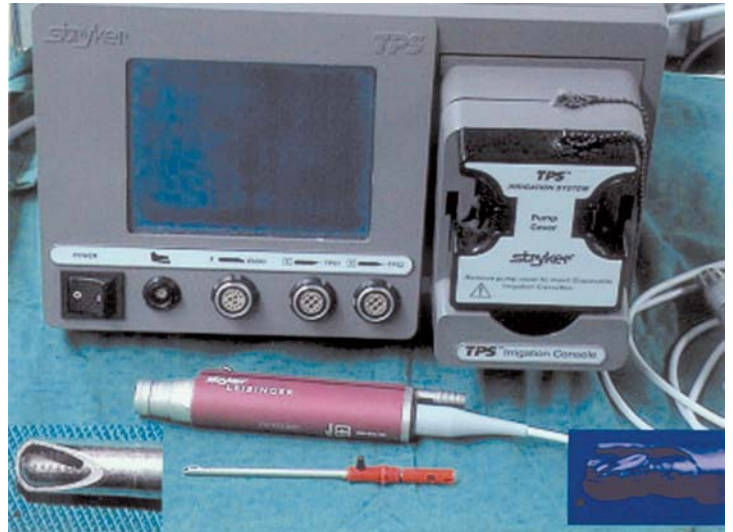

Fig. (2): The endonasal incisions: (A) partial (limited) septal transfixion incision. (B) Complete septal transfixion incision. (C) Intercartilagenous incision.

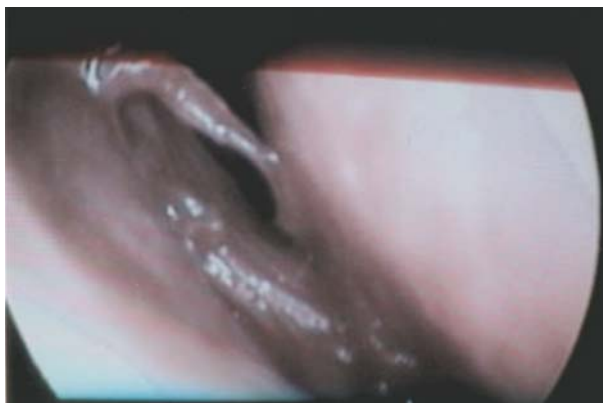
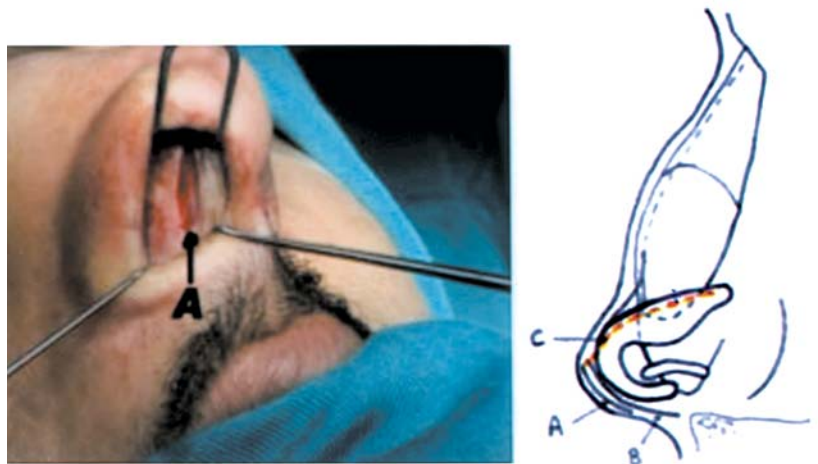


Fig. (3): Identification of the angular vessels to the nasal dorsum.

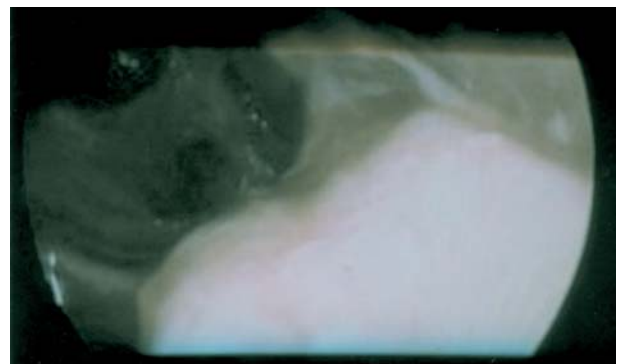


Fig. (4): Endoscopic view of nasal dorsum.

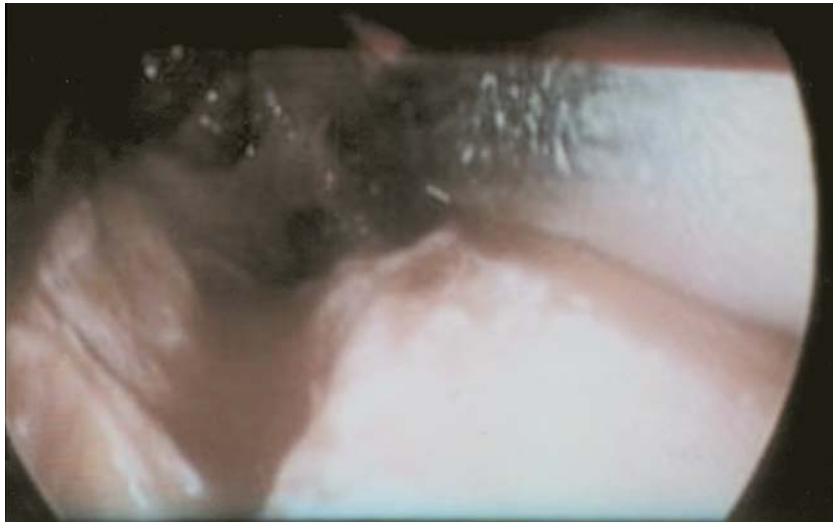


Fig. (5): The microdebrider removing the nasal hump.

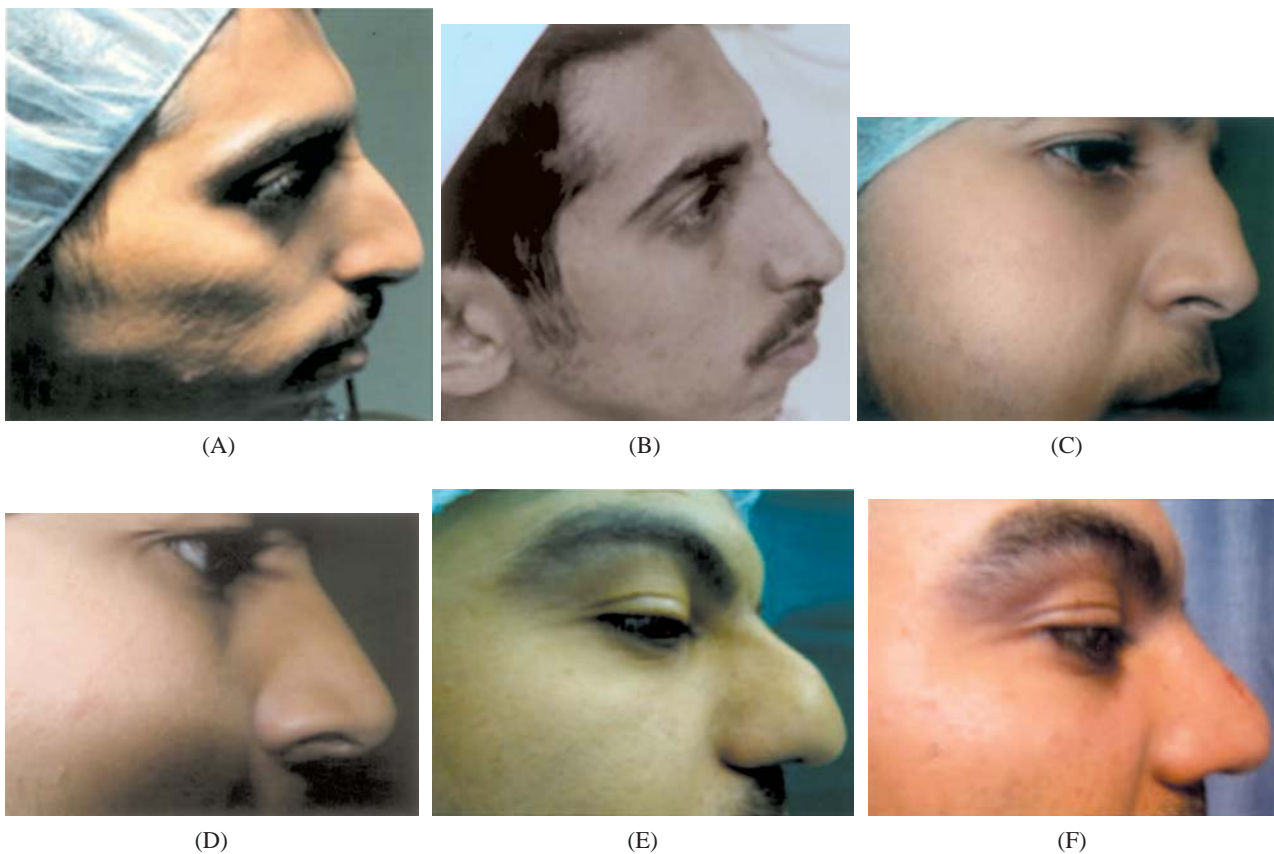


Fig. (6): (A,C & E): Preoperative photos of 3 patients with high nasal hump involved in this study. (B): One-week, (D): Eight-months and (F): Twelve-months postoperative photos of the same patients showing satisfactory results.

and sinus physiology together with rapid advances in the technology of fiberoptic endoscopes and the surgical instruments. As a consequence, more recently (in the late 1990s), the idea of use of nasal endoscopes in cosmetic rhinoplasty has risen with reporting its precision in diagnosis and treatment [11]. In 2001, Kim and Kim [1] performed lateral osteotomies using an endoscope through intraoral

incisions. They stated that these endoscopic repairs for deviated nose were quite helpful for visual confirmation and accurate correction with no complications occurred in their series of patients.

While in standard closed technique rhinoplasty, reduction of the nasal dorsum is performed depending only on palpation [12], the addition of nasal

endoscopes provides direct visualization of the nasal dorsum up to the frontonasal junction and permitting its reduction under direct vision (Fig. 4). Also, the use of endoscopes for nasal dorsum reduction does not need external incisions or extensive dissection as that required for open structure rhinoplasty where exposure of the upper one third (bony nasal dorsum) is still limited [3].

A great advance in the surgical instrumentation of rhinology is the use of powered microdebridors (Fig. 1) for surgical treatment of the nose and paranasal sinuses [5]. This technology has been used in endoscopic sinus surgery [13,14], facial liposuction [15], dacryocystorhinostomy [16]. The use of powered instrumentation allows surgery to proceed with decreased intraoperative bleeding and with faster healing than with standard techniques [17], due to its sharp precise tissue removal. Additionally, recent technological advances in bur design have allowed the development of shielded vacuum-assisted burs for the removal of dense bone. These devices have been used in procedures such as the drill out of the floor of the frontal sinuses, as in a modified Lothrop procedure [18].

The excellent postoperative aesthetic results in this study (Fig. 6) showed that the use of powered microdebridors in dorsal nasal reduction (Fig. 5) has the potential to decrease soft tissue trauma and allowing good contouring of the bone without the trauma of rasping. In addition the use of the powered drill decreases the incidence of bony dorsal irregularities after rhinoplasty. This is in agreement with the results noted by Becker et al. [19]. Another advantage of this method is the ability to refine the bony nasal dorsum following osteotomies. When irregularities in dorsal contour occur following osteotomy, the use of powered drill allows more precise polishing, without the difficulty in manipulating mobile fragments as sometimes seen with rasps.

Thus with the excellent visualization afforded by the use of endoscopes (Fig. 4) and with the precision of microdebridors (Fig. 5), this study demonstrates an excellent technique for nasal dorsum reduction during cosmetic rhinoplasty. This technique has been used in 20 patients with reduced intraoperative bleeding and the postoperative ecchymosis and edema. All patients in this study had an excellent postoperative aesthetic results with no complications reported in any of them for an average follow up period of 18 months postoperatively. Our results were comparable to those shown by Krouse [20]. Similarly and in his accordance, as the angular vessels can be identified

prior to their injury, they can be either avoided or cauterized and divided under direct vision. This can lessen the intraoperative bleeding and the perioperative swelling and ecchymosis. On the other hand and in contrast to the previously mentioned Krouse study, the microdebrider was very efficient for removal of the whole nasal hump (cartilaginous and bony components) in our study and not only the bony part. Also, in our study only limited (partial) transfixion incision was used in all patients without need for complete transfixion incision used in Krouse's study. As the latter incision cases loss of the attachment of the medial crural footplates to the caudal septum, which is a major source of tip support, it leads to decreased tip projection [21].

Conclusion:

The use of nasal endoscopes during rhinoplasty provides excellent direct visualization of the nasal dorsum and allows its precise contouring using the standard microdebridors resulting in excellent cosmetic results. This technique is easy, safe, efficient and minimally invasive with less surgical trauma. Also, through visualization of the nasal dorsum this technique provides a better way for teaching rhinoplasty techniques. Lastly, but not least, the use of this technique should be considered in situations requiring fine and precise contouring of the nasal dorsum.

REFERENCES

- 1- Kim J.T. and Kim S.K.: Endoscopically assisted, intraorally approached corrective rhinoplasty. *Plast. Reconstr. Surg.*, 108: 199, 2001.
- 2- Toriumi D.M. and Johnson C.M.: Open structure rhinoplasty. *Fac. Plast. Clin. North Am.*, 1: 1, 1993.
- 3- Elsayh N.: Basic open rhinoplasty - comparison of the open and closed techniques. In Elsayh N. (ed): *Plastic and reconstructive surgery of the nose-part I: cosmetic surgery of the nose (rhinoplasty)* - Chapter 4 p. 39-41, 2000.
- 4- Bafaqeeh S.A. and Al-Qattan M.M.: Open rhinoplasty: Columellar scar analysis in an Arabian Population. *Plast. Reconstr. Surg.*, 112 (4): 1226, 1998.
- 5- Krouse J.H. and Christmas D.A.: *Powered endoscopic sinus surgery*. Baltimore: Williams & Wilkins, 1997.
- 6- Messerklinger W.: *Endoscopy of the nose*. Baltimore - Munich: Urban & Schwarzenberg, 1968.
- 7- Stammberger H.: *Functional endoscopic sinus surgery*. Philadelphia: BC Decker, 1991.
- 8- Kennedy D.W.: *Functional endoscopic sinus surgery*. *Arch Otolaryngol*, 111: 643, 1985.
- 9- Kennedy D.W., Zinreich S.J. and Rosenbaum A.: *Functional endoscopic sinus surgery: theory and diagnosis*. *Arch. Otolaryngol.*, 111: 576, 1985.

- 10- Kennedy D.W., Shaman P. and Han W.: Complications of ethmoidectomy: a surgery of follow of the American Academy of Otolaryngol-Head and Neck Surgery. *Otolaryngol. Head Neck Surg.*, 111: 589, 1994.
- 11- Hochberg J., Faria-Correa M.A. and Ramadam H.: Development of an instrument for endoscopic nasal surgery. *Clin. Plast. Surg.*, 22: 781, 1995.
- 12- Mayer T.G. and Fleming R.W.: The nasal dorsum-open approach. *Fac. Plast. Surg.*, 5: 143, 1988.
- 13- Setliff R.C. and Parsons D.S.: The "Hummer": new instrumentation for functional endoscopic sinus surgery. *Am. J. Rhinol.*, 8: 275, 1994.
- 14- Christmas D.A. and Krouse J.H.: Powered instrumentation in functional endoscopic sinus surgery I: surgical technique. *Ear Nose Throat J.*, 75: 33, 1996.
- 15- Gross C.W., Becker D.G. and Lindsey V.H.: The soft tissue shaving procedure for removal of adipose tissue. *Arch. Otolaryngol. Head Neck Surg.*, 121: 1117, 1995.
- 16- Mercandetti M. and Mirante J.P.: Powered endonasal dacryocystorhinostomy. In: Krouse J.H. and Christmas D.A. (eds): *Powered endoscopic sinus surgery*. Baltimore: Williams & Wilkins, 1997.
- 17- Krouse J.H. and Christmas D.A.: Powered instrumentation in functional endoscopic sinus surgery II: a comparative study. *Ear Nose Throat J.*, 75: 42, 1996.
- 18- Gross C.W. and Becker D.G.: Power instrumentation in endoscopic sinus surgery. *Otolaryngol. Head Neck Surg.*, 7: 236, 1996.
- 19- Becker D.G., Toriumi D.M., Gross C.W. and Tardy M.E. Jr.: Powered instrumentation for dorsal reduction. *Facial. Plast. Surg.*, 13: 291, 1997.
- 20- Krouse J.H.: Endoscopic-powered rhinoplasty. *The Journal of Otolaryngol.*, 28 (5): 282, 1999.
- 21- Elsahy N.: Basic endonasal rhinoplasty: incisions. In Elsahy N. (ed): *Plastic and reconstructive surgery of the nose Part 1: cosmetic surgery of the nose (rhinoplasty)-Chapter 3* p. 19-23, 2000.